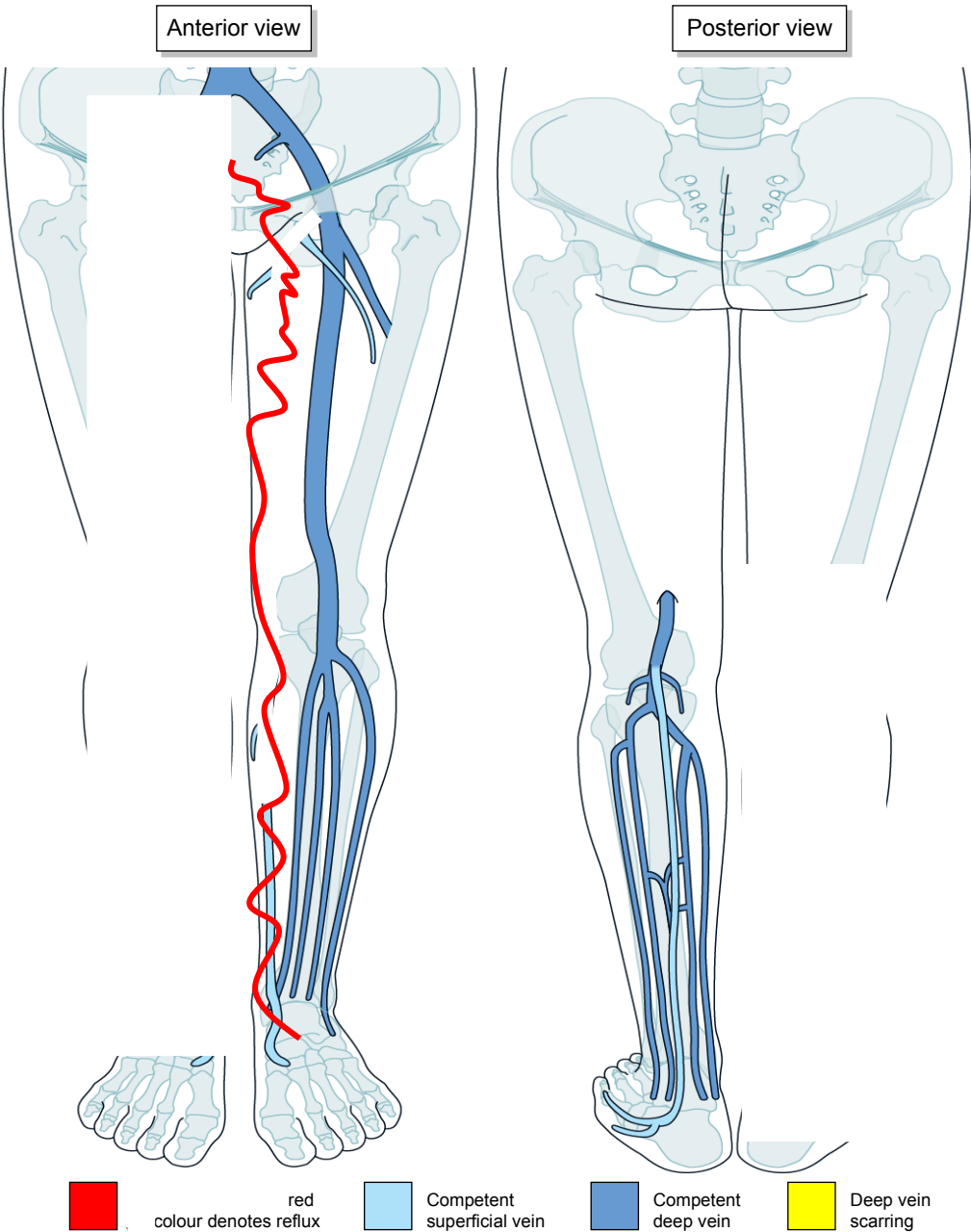


Vascular lab report

Assessed by: Suleman Choudhury



US Doppler lower limb veins Lt:

The Sapheno-Femoral Junction (SFJ) appears patent and competent.

The Greater Saphenous vein (GSV) was not present – probably due to previous foam sclerotherapy

There appears to be varicose veins originating from pelvic source which course medially (3.6mm) to the foot.

The Sapheno-Popliteal Junction (SPJ) and Short Saphenous vein (SSV) are patent and competent.

All deep veins are all patent and competent.

No incompetent perforators detected.
